

AUTOMATED LEVEL SET SEGMENTATION OF THE TRABECULAR CENTRUM IN HEALTHY AND METASTATIC VERTABRAE

Agarwal P, Hardisty M, Skriskas T, Whyne CM

Sunnybrook & Women's College Health Sciences Centre, University of Toronto, Toronto, ON, Canada.

INTRODUCTION: The vertebral column is the most frequent site of metastatic involvement of the skeleton, with up to 1/3 of all cancer patients developing tumors in the spine. Utilizing CT imaging, detection of tumors in the spine can be accomplished using a voxel intensity classification method, however to produce accurate volume estimates requires the identification of a precise region of interest (ROI). Atlas based registration is able to create a fairly accurate segmentation of an entire vertebral body; however this method is not sufficient to differentiate the trabecular centrum from the vertebral cortical shell. Inclusion of the cortical shell in the assessment of metastatic involvement can create problems for tumor quantification in mixed and blastic metastases as the cortical shell displays similar voxel intensity to blastic tumor tissue. The Level Set method works to evolve geometric interfaces through a combination of image intensity and curvature propagation. It is hypothesized that Level Set segmentation can be used to refine initial ROI estimates to isolate only the trabecular bone centrum of vertebrae and thus provide a method to improve tumor quantification accuracy in the metastatic spine.

METHODS: CT scans of 21 vertebral bodies (14 healthy and 7 involving metastatic tumors), ranging in levels from T7 to L5 were obtained from 12 patients using a GE Lightspeed Plus CT Scanner (120kVp, 1.25mm slice interval, and 2.5mm slice thickness). The metastatic vertebrae analyzed contained lytic, blastic and mixed lesions. Lytic lesions breached the cortical shell in 3 cases and blastic tumor was directly adjacent to the cortical shell in 3 cases, representing 2 particular challenges in automated segmentation. Using demons atlas-based segmentation (Amira, ITK), an initial ROI containing the entire vertebral body was defined. To isolate the trabecular centrum, an iterative process using a Level Set Shape Detection Filter (ITK) was applied. Level Set methods utilize a higher dimension function, to track the contour of the propagating curve. By exploiting the contrast in voxel intensities between cortical shell and trabecular regions, a sigmoid filter was applied to the vertebral scan to create the required speed function. The curvature and propagation weighting terms control the curvature propagation to minimize exclusion of the desired trabecular centrum. First, a 3D Shape Detection filter was used to eliminate any extra-vertebral space remaining in the atlas based segmentation. By applying a high curvature weighting, the segmentation was limited from propagating into any lytic tumors that had breached the cortical shell. Next, the resulting segmentation moved further inward using a 3D Shape Detection algorithm with a constant speed function and low number of iterations. A fill hole filter (Amira) was then applied to each axial scan slice to eliminate cases where the curve may have propagated into a lytic tumor removing it from the ROI. Finally, axial slices of the scan and resulting curve were extracted and a 2D Level Set algorithm was run to remove any remaining cortical shell. A high curvature weighting term helped to ensure the process did not exclude any blastic tumors connected to the cortical shell. In order to quantify the extent of cortical shell removal, intensity thresholds were compared from two voxel intensity histograms created for each healthy vertebral body: 1) a manual segmentation including cortical shell and 2) a ROI representing the trabecular centrum determined using the Level Set method. A further validation of the Level Set methods was accomplished by comparing the results for both the healthy and metastatic segmentation of the trabecular bone centrum to a gold standard manual segmentation of the same region.

RESULTS: Prior to shell removal $20.8\% \pm 5.5\%$ of the vertebral body segmentations was classified as high intensity cortical bone. After application of the Level Set algorithm high intensity bone only represented $2.9\% \pm 0.5\%$ of the segmentation. Comparing the automated segmentations of the trabecular bone centrum (healthy and metastatic) to manual segmentations yielded a concurrency rate of $90.8\% \pm 2.3\%$. For scans in which a lytic tumor had breached the cortical shell the concurrency rate was $88.6\% \pm 1.7\%$. Scans containing a blastic tumor adjacent to the cortical shell exhibited a concurrency rate of $90.3\% \pm 2.5\%$.

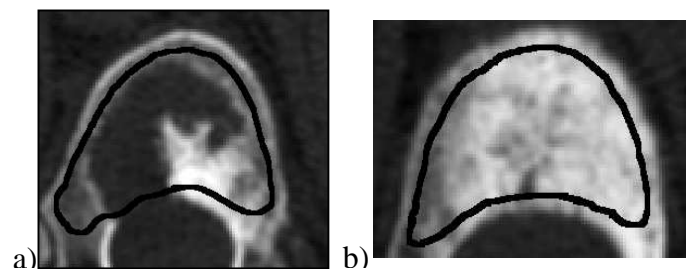


Figure 1: Automated trabecular centrum segmentation in vertebrae exhibiting a) lytic tumor that has breached the cortical shell and b) blastic tumor adjacent to cortical shell.

DISCUSSION: Level Set Shape Detection methods are well suited for isolating the trabecular region in both healthy and metastatically involved vertebral bodies. By applying a large curvature term weighting, the ability of the curve to propagate into tumors and eliminate them from the ROI is limited. The greatest errors in trabecular bone isolation occurred as a result of partial inclusion of the vertebral endplates; however, this is not a large concern as endplates contain few high intensity voxels, which might be incorrectly classified as blastic tumor tissue. This algorithm can successfully perform automated segmentation of a vertebral body trabecular centrum to yield an appropriate ROI for quantitative assessment of metastatic disease and may be adapted to trabecular region segmentation in other bones exhibiting a rounded cross sectional geometry.

ACKNOWLEDGMENTS: Support for this work was provided by the Canadian Breast Cancer Research Initiative